

Tissue microarrays in urology

IOBAL S. SHERGILL, ALEX FREEMAN* and ANTHONY R. MUNDY

Institute of Urology, and *Histopathology Department, University College Hospital, London, UK

Accepted for publication 4 November 2003

KEYWORDS

urology, prostate, kidney, bladder, methods, clinical application

INTRODUCTION

The Human Genome Project has provided the sequence for almost every gene, thus laying the foundations for a greater understanding of human diseases (<http://www.ncbi.nlm.nih.gov>). In parallel, molecular biology techniques have emerged to enhance the understanding of gene function, and for identifying targets for developing novel therapies in oncology [1]. In urology, DNA microarrays have allowed many genes to be identified in prostate, kidney and bladder cancer which may have important roles as diagnostic and prognostic markers for individual patients [2–4]. However, DNA microarrays are expensive, time-consuming and complicated to analyse, limiting their use in the hospital setting.

Traditionally the validation of novel markers, and their introduction into routine clinical medicine, is by using immunohistochemistry on formalin-fixed and paraffin-embedded tissue. Although this method provides extremely accurate, representative and reliable outcomes, evaluating several markers in many clinical specimens is time-consuming and labour intensive. In addition, vital tissue resources are used, as each histological block of tissue is typically exhausted after 50–100 sections. Thus a bottleneck has been created between the recent discoveries of novel markers and their validation on clinical specimens.

In an effort to overcome the limitations of the standard histological method, the tissue microarray (TMA) was introduced [5]. Historically, TMAs are based on the principles of a 'sausage' block method, described in 1986 [6]. In this method, 'rods' of tissue from different specimens (1 mm thick) were wrapped in a specially prepared sheet of small intestine. The resultant 'sausage' of tissues

was then embedded in a paraffin-wax block, allowing numerous sections to be cut. Although many tissue specimens were examined under identical conditions simultaneously with this technique, the inability to satisfactorily identify individual 'rods' obtained from the host tissue limited interpretation and any meaningful outcomes. Subsequently, the TMA was developed.

The TMA is a high-throughput technique to assess thousands of different cores of pathological tissue simultaneously using morphological and molecular analyses, e.g. immunohistochemistry and *in situ* hybridization, whilst maintaining an accurate and efficient method of identifying each specific section. Using this technique an economy in cutting and staining can also be used, with an unprecedented level of standardisation within one TMA experiment, as all the experimental conditions for all the cores are identical. It is now firmly established that the TMA can significantly accelerate the processing of very many tissue specimens, with excellent quality, good reliability and preservation of original tissue.

METHOD

A haematoxylin and eosin-stained slide is marked with the areas of interest, such as a cancer and normal tissue, by a histopathologist (Fig. 1). The corresponding region from a paraffin-embedded block (the donor block) is carefully selected. A tissue-arraying instrument (Fig. 2) is used to acquire a tissue core from the donor block, using a thin-walled needle with an inner diameter of 0.6 mm. Held in an X-Y precision guide this core is then placed in an empty paraffin block (the recipient block) at a specifically assigned location. This sampling process is then repeated many times from different regions of the same donor block, or from many different donor blocks, until hundreds, or even thousands, of cores are placed into the recipient block, producing the final TMA block.

After constructing the array block many sections can be cut using the traditional

method (microtome and water bath), or using a specially designed adhesive-coated tape sectioning system, by which an adhesive tape is placed on the face of each section before it is cut with a microtome, and the section subsequently 'cross linked' to a microscope slide using ultraviolet light. Using either technique, 4 µm sections are typically cut, with all the cores in an identical configuration, ready for subsequent morphological or molecular analysis. As an example, if the original donor blocks are 5 mm thick, then 1250 sections can be obtained from each TMA block. In addition, if an array contains 300 cores, this technique would produce 375 000 different results from one TMA block!

At present there are no standardized published guidelines for TMA design, but the most important feature of the layout is to allow easy analysis of the arrays. This may be achieved by including control sections of normal tissue at specific locations and by producing an asymmetric array.

Currently, most TMAs (80%) are being used for immunohistochemistry (Fig. 3), with the remaining 20% being investigated by *in situ* hybridization techniques (<http://www.pathology.pitt.edu>). Immunohistochemistry is used in the standard way, with some significant advantages. As all the cores on one slide are tested simultaneously there is a remarkable standardisation of antigen retrieval, incubation times with primary antibodies, concentrations, temperatures and wash conditions. In addition, only small quantities of reagent are needed for the experiments. Subsequently, using a simple computer spreadsheet program the locations of the cores on the TMA can be rapidly compared with clinical and pathological data.

APPLICATIONS OF TMAs IN UROLOGY

The applications of TMA in urology are extremely wide ranging. The first published article using a TMA on genitourinary tissue

FIG. 1. A slide stained with haematoxylin and eosin, marked with areas of prostate cancer (green) and normal prostate (red).

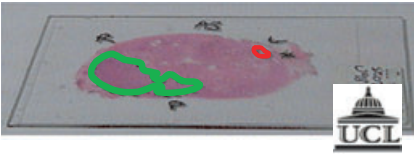


FIG. 2. A commercial TMA machine.




FIG. 3. Prostate cancer TMA core stained with anti-MIB-1 antibody (yellow arrows) at low power (A, $\times 4$) and at higher power (B, $\times 40$).

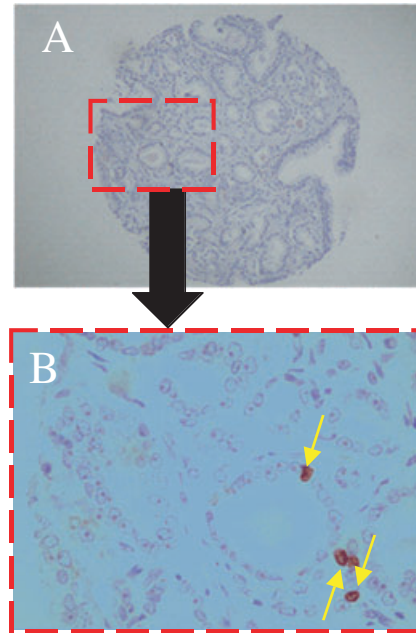
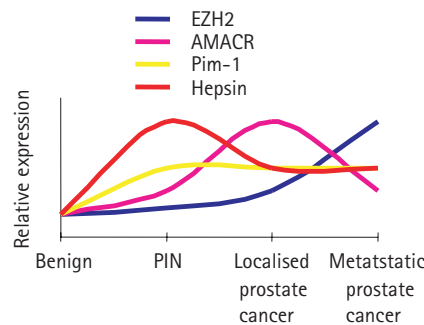


FIG. 4. The expression of novel markers in prostate cancer progression TMAs.



involved the investigation of gene amplifications in prostate cancer using fluorescent *in situ* hybridization [7]. Subsequently, reports on many benign and malignant urological specimens have been published. Conventionally, three categories of TMA are defined, according to the range of tissue sampled and the clinical follow-up available. These will be used to describe the relevant TMA studies in urological publications.

MULTI-TUMOUR ARRAYS

Many tumour types are sampled from a diverse set of donor blocks and arrayed on one recipient TMA block. With this type of TMA, a large group of tumours from the genitourinary tract can then be expeditiously screened for the presence or absence of newly identified genes. Using such an approach the presence of amplifications of three different oncogenes across a spectrum of nearly 400 tumours, including kidney, bladder, prostate and testis cancers, were assessed [8]. This experiment was completed within a week! The results obtained from this study were remarkably consistent with previously published findings on amplifications in urological tumours.

TUMOUR PROGRESSION ARRAYS

Morphological and molecular changes through the different stages of tumour progression, of one particular tumour type, can be assessed in tumour progression TMAs. For example, in prostate cancer the construction of such an array would involve sampling normal prostate, BPH, prostatic intraepithelial neoplasia (PIN) and different stages of prostate cancer, from localised disease to metastatic cancer.

In one of the most significant recent papers in prostate cancer a tumour progression array was used to show that the expression of a

novel protein, EZH2, correlated with aggressiveness of disease [9]. There was low expression in benign prostate and PIN, whereas levels were intermediate in localised prostate cancer, with the highest levels in metastatic disease (Fig. 4). The expression of other novel markers in prostate cancer has also been assessed using tumour progression arrays (Fig. 4). Interestingly, it appears that proteins such as α -methylacyl coenzyme A racemase (AMACR), Pim-1 and hepsin may only have limited value in prediction, as they do not appear to have a directly proportional relationship to different stages of prostate cancer progression [10,11].

Similar progression TMAs have been used in renal and bladder cancer, but with less dramatic findings. In a study evaluating genes identified by DNA microarray analysis in renal cancer [3], TMAs identified vimentin expression to be more frequent in Fuhrman grade II (44%) and grade III (42%) clear cell carcinomas than in grade I tumours (13%). In addition, vimentin expression was more common in stage T3/T4 cancers (60%) than in pT1/T2 tumours (40%), although this finding was not statistically significant. This study also showed a clear association between vimentin expression and tumour progression amongst different histological subtypes. Similarly, Vispaa *et al.* [12] also showed an increase in staining of Ki-67 and gelsolin with increasing tumour grade in RCC. Primary urothelial carcinomas have also been investigated in tumour progression arrays and the expression of gelsolin was lower in dysplasia and carcinoma *in situ* than in benign urothelium [13].

PROGNOSTIC (PATIENT OUTCOME) ARRAYS

Whilst multi-tumour and progression arrays provide useful diagnostic information, correlation of TMA-derived data with clinical follow-up, to assess prognosis or patient outcome, is of significant interest to clinicians and their patients. One such example is the study involving the EZH2 protein [9]. In addition to its use as a marker of prostate cancer progression, Varambally *et al.* [9] showed that the degree of expression of this protein was related to outcome after radical prostatectomy. Whilst strong expression was associated with recurrence of tumour after surgery in a third of patients, there was weak EZH2 staining in only 9% of those with clinical failure. Similar associations with prognosis were described with the proteins

hepsin [10] and AMACR [11] using patient outcome arrays.

Patient outcome arrays have also been described in renal and bladder cancer to validate novel markers. In their study of 532 RCC samples and six normal kidneys, Hoch *et al.* [3] found an association between vimentin expression and poor prognosis of patients with kidney cancer, whereas Richter *et al.* [14] analysed 2317 specimens of bladder cancer for cyclin E protein expression using immunohistochemistry and cyclin E gene amplifications by fluorescence *in situ* hybridization, finding that protein expression and amplification directly correlated with clinical outcome.

Recently it was suggested that combinations of expression of novel markers may be of more benefit in predicting prognosis [15]. Rhodes *et al.* [15] investigated 14 candidate prognostic markers in prostate cancer, including hepsin, AMACR, E-cadherin and EZH2. They found that only the ratio of EZH2 to E-cadherin staining was statistically associated with prostate cancer recurrence after radical prostatectomy. This approach may be useful in identifying patients who are at high risk of recurrence, and therefore providing them with alternative and appropriate treatment. As TMAs incorporate a high-throughput approach, they are very well suited for this 'multiplex biomarker approach'.

LIMITATIONS

The results of TMA must reliably indicate whether markers expressed in the core of tissue sampled correspond to information from standard whole sections. Criticism has been levelled because the small cores of tissue used in TMAs may not be fully representative of whole tumours. This would have particularly important implications in heterogeneous tumours such as prostate cancer. Validation studies have critically evaluated this issue, comparing TMAs with whole-mount sections in prostate cancer [16] and bladder cancer [17]. The conclusion from these studies was that there is an excellent correlation between data obtained from TMA and standard histopathological techniques.

In addition, there is also the inevitable risk of losing some cores by sampling errors (lack of tumour in the arrayed sample), damaged tissue (caused by heat or crush artefacts) and

empty spots (total lack of tissue at some positions), and this has been estimated at 15–33% [8,14]. In our experience the incidence is lower, at $\approx 10\%$ (Shergill *et al.* unpublished observations).

The optimum number of cores per specimen sampled has to be comprehensive enough to reduce the potential error rate attributable to tissue heterogeneity, whilst accounting for the inevitable risk of losing some cores. Increasing the number of cores to compensate for inevitable losses will only confer a slightly higher rate of validity, with the disadvantage of additional labour in creating more arrays and lack of efficiency in processing the tissues. In the most extensive study investigating validation in prostate cancer Rubin *et al.* [16] found that 3–4 cores was the optimum necessary to predict the outcome after radical prostatectomy for localised prostate cancer. Similarly, Nocito *et al.* [17] found that combined data from four replicate bladder tumour TMAs were sufficient to accurately detect clinicopathological correlations.

TISSUE ARRAY RESEARCH PROGRAMME

The National Human Genome Research Institute (NHGRI) and the National Cancer Institute (NCI) have created the Tissue Array Research Program (TARP) in an attempt to promote research and development of TMAs (<http://www.resources.nci.nih.gov/tarp>). The overall aims of TARP are to produce TMAs for use by the research community, to provide assistance in arraying unique tissue materials, such as those from clinical trial groups, and to provide training, workshops and protocols on TMA technology. The NHGRI lead the development of TMA technology whereas the NCI coordinate the construction of TMAs and enable them to be accessible to the research community.

CONCLUSION

At present TMAs are a high throughput research tool for investigating candidate genes, identified by molecular biology techniques, at the protein level. Studies have shown their accuracy and reliability compared to standard histological techniques, and their good correlation with clinicopathological information to determine tumour development, progression and prediction of outcome. It is anticipated that this method

will have a major effect and an expanding role in the diagnosis, prognosis and development of novel therapies for individual patients in clinical urology.

CONFLICT OF INTEREST

None declared.

REFERENCES

- Williamson M, Naaby-Hansen S, Masters JR. 21st century molecular biology in urology. *BJU Int* 2001; **88**: 451–7
- Rhodes DR, Barrette TR, Rubin MA, Ghosh D, Chinnaiyan A. Meta-analysis of microarrays: interstudy validation of gene expression profiles reveals pathway dysregulation in prostate cancer. *Cancer Res* 2002; **62**: 4427–33
- Moch H, Schraml P, Bubendorf L *et al.* High-throughput tissue microarray analysis to evaluate genes uncovered by cDNA microarray screening in renal cell carcinoma. *Am J Pathol* 1999; **154**: 981–6
- Sanchez-Carbayo M. Use of high-throughput DNA microarrays to identify biomarkers for bladder cancer. *Clin Chem* 2003; **49**: 23–31
- Kononen J, Bubendorf L, Kallioniemi A *et al.* Tissue microarrays for high-throughput molecular profiling of tumor specimens. *Nat Med* 1998; **4**: 844–7
- Battifora H. The multitumor (sausage) tissue block: novel method for immunohistochemical antibody testing. *Laboratory Invest* 1986; **55**: 24–8
- Bubendorf L, Kononen J, Koivisto P *et al.* Survey of gene amplifications during prostate cancer progression by high-throughput fluorescence *in situ* hybridization on tissue microarrays. *Cancer Res* 1999; **59**: 803–6
- Schraml P, Kononen J, Bubendorf L *et al.* Tissue microarrays for gene amplification surveys in many different tumor types. *Clin Cancer Res* 1999; **5**: 1966–75
- Varambally S, Dhanasekaran SM, Zhou M *et al.* The polycomb group protein EZH2 is involved in progression of prostate cancer. *Nature* 2002; **419**: 624–9
- Dhanasekaran SM, Barrette TR, Ghosh D *et al.* Delineation of prognostic biomarkers in prostate cancer. *Nature* 2001; **412**: 822–6
- Rubin MA, Zhou M, Dhanasekaran SM

- et al.* Alpha-Methylacyl coenzyme A racemase as a tissue biomarker for prostate cancer. *JAMA* 2002; **287**: 1662–70
- 12 **Vispaa H, Bui M, Huang Y *et al.*** Correlation of Ki-67 and gelsolin expression to clinical outcome in renal clear cell carcinoma. *Urology* 2003; **61**: 845–50
- 13 **Rao J, Seligson D, Visapaa H *et al.*** Tissue microarray analysis of cytoskeletal actin-associated biomarkers gelsolin and E-cadherin in urothelial carcinoma. *Cancer* 2002; **95**: 1247–57
- 14 **Richter J, Wagner U, Kononen J *et al.*** High-throughput tissue microarray analysis of cyclin E gene amplification and overexpression in urinary bladder cancer. *Am J Pathol* 2000; **157**: 787–94
- 15 **Rhodes DR, Sanda MG, Otte AP, Chinnaiyan AM, Rubin MA.** Multiplex biomarker approach for determining risk of prostate-specific antigen-defined recurrence of prostate cancer. *JNCI* 2003; **95**: 661–8
- 16 **Rubin MA, Dunn R, Strawderman M, Pienta KJ.** Tissue microarray sampling strategy for prostate cancer biomarker analysis. *Am J Surg Pathol* 2002; **26**: 312–9
- 17 **Nocito A, Bubendorf L, Maria Tinner E *et al.*** Microarrays of bladder cancer tissue are highly representative of proliferation index and histological grade. *J Pathol* 2001; **194**: 349–57
- Correspondence:** Iqbal S. Shergill, Specialist Registrar in Urology (London Deanery), Broomfield Hospital, Court Road, Chelmsford, Essex, CM1 7ET, UK.
e-mail: super_iqi@yahoo.co.uk
- Abbreviations:** TMA, tissue microarray; PIN, prostatic intraepithelial neoplasia; AMACR, alpha-methylacyl coenzyme A racemase; NHGRI, National Human Genome Research Institute; NCI, National Cancer Institute; TARP, Tissue Array Research Program.